

Age-related Changes Resembling Fibrocystic Disease in Iodine-Blocked Rat Breasts

Theodore B. Krouse, MD; Bernard A. Eskin, MD; Jalal Mobini, MD

• It has been reported that dietary restriction and chemical blockade of iodine causes histopathologic changes in peripubertal female rat breasts. This study extended the age range to include midreproductive life and perimenopausal rats; there is a wider spectrum of structural alterations that are associated with the older breast, with sodium perchlorate as the blocking agent. In 16-week-old rats, breasts showed general increased parenchymal activity and growth, regressing after removal of the block. In 42-week-old rats, breasts showed noticeable calcospherite deposition, intralobular fibrosis, and cystic changes resembling human fibrocystic disease. In 52-week-old rats, breasts exhibited atypical lobules cytologically, papillomatosis, sclerosing adenosis, calcifications, and a lobular transformation of a histologically dysplastic type. It is in the older rat that experiments will more closely parallel the human condition.

(Arch Pathol Lab Med 103:631-634, 1979)

Two human breast diseases of paramount importance clinically are fibrocystic disease and carcinoma. Yet, despite well-known age-related statistics, a large number of in vivo studies of mammary carcinogenesis have been performed over many decades using the peripubertal rat as the animal model.

Now, within our laboratory in the past decade, it has been demonstrated that an inadequate supply of iodine resulted in histopathologic alterations in the breast parenchyma of rats. In an initial study with peripubertal rats, such deficiency enhanced the response of rat breasts to the sex hormones. The changes were clearly distinguishable from those induced by estrogen or testosterone and were lesions that mimicked fibrocystic disease as found in the human.¹ A subsequent study using peripubertal rats subjected to iodine-deficient diets along with propylthiouracil and estrogen, singly or in combination, also resulted in lesions resembling the changes in fibrocystic disease of the human breast. The more severe changes were associated with the combined use of all agents under the effect of an iodine-deficient diet.² A more selective approach to iodine restriction to the breast was effected by using an iodine-blocking agent, sodium perchlorate. The perchlorate

block was used either alone or with thyroxine or estrogen or in combination. When the agents were used in combination under this iodine-deficient blockade, focal cytologic atypia was found at the terminal duct-lobule level and at the large duct level.³ This present study in contrast to previous work in our laboratory as well as in other laboratories uses rats of differing ages.

MATERIALS AND METHODS

A total of 135 Sprague-Dawley female rats were used in this study. Of these, the major groups were 45 rats of 16 weeks of age (weight range, 244 to 320 g), 45 rats of 42 weeks (weight range, 264 to 378 g), and 45 rats of 52 weeks (weight range, 292 to 467 g). Each group was then divided into equal subgroups of 15 each that were then categorized as controls, as a group exposed to perchlorate-treated drinking water for two weeks, and as a group exposed to perchlorate-treated drinking water two weeks, with the exception that in the last 16 hours within this two-week period access was permitted again to only untreated drinking water. At the end of the two-week period, all rats were given intraperitoneal injections of 1 μ Ci of diatrizoate sodium I 125 suspended in 0.1 mL of 0.9% NaCl solution and then killed. The three inferior and bilateral abdominal mammary glands of each rat were studied.

Accepted for publication March 2, 1979.
From the Departments of Pathology (Drs Krouse and Mobini) and Obstetrics and Gynecology (Dr Eskin), Medical College of Pennsylvania, Philadelphia.
Read before the 68th annual meeting of the American Association of Cancer Research, Denver, May 20, 1977.
Reprint requests to Department of Pathology, Division of Anatomic Pathology, Medical College of Pennsylvania, 3300 Henry Ave, Philadelphia, PA 19129 (Dr Krouse).

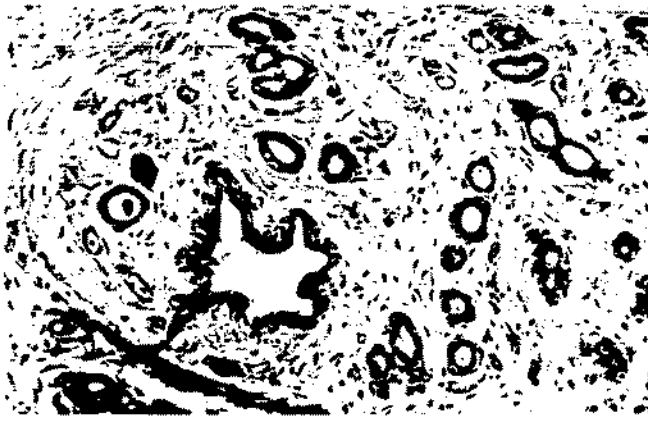


Fig 1.—Rat breast, 16 weeks old (group 1, perchlorate blockade). Swirling fibroblastic proliferation about major duct, entrapping proliferated secondary ducts (hematoxylin-eosin, $\times 252$).



Fig 2.—Rat breast, 42 weeks old (group 2, perchlorate blockade). Striking focal calcifications are noted at duct and lobular levels with pattern further obscured by fibrous tissue encroachment (hematoxylin-eosin, $\times 252$).



Fig 3.—Rat breast, 52 weeks old (group 3, perchlorate blockade). Intralobular fibrous tissue proliferation resembling sclerosing adenosis of human (hematoxylin-eosin, $\times 168$).

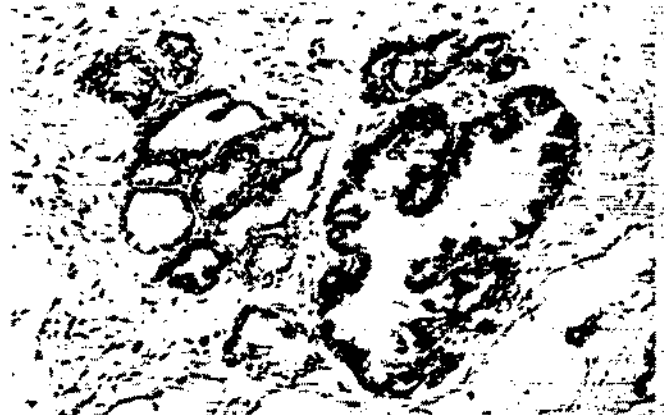

Fig 4.—Rat breast, 52 weeks old (group 3, perchlorate blockade). Atypia is present in microcystic site with disturbed polarity, piling-up of cells, and attainment of papillomatous character (hematoxylin-eosin, $\times 252$).

Iodine Uptake Results

The iodine uptake results, in summary, showed a percentage blockade ranging from 60% in the youngest rats to 25% in the oldest rats. On release of the blockade by reexposure to untreated water, there was an average of 30% restitution of iodine uptake back to the control level in those rats used as controls.

Histologic Interpretation

Sixteen-Week-Old Rat Breasts (Group 1).—In the controls, one sees an essentially inactive breast pattern manifested by scattered ducts set in an abundant adipose stroma with minimal lobule formation. After two weeks of perchlorate blockade, there is a prominent lobular hyperplasia and concomitant secretory activity imparting a "honey-combed" character to the lobules. In some areas, there is a pattern of

mild intralobular as well as interlobular and purely adipose-field stromal proliferation well away from the lobules. Focally, one also notes sites of a more intense swirling fibrous proliferation around the larger ducts. Within this fibrous expansion, numerous secondary ducts have proliferated and seem entrapped by the extending fibroblastic process (Fig 1). On access to water ad libitum for the final 16 hours, there is regression of the lobular hyperplasia, duct proliferation, and dilation.

Forty-two-Week-Old Rat Breasts (Group 2).—In the controls at 42 weeks of age, one notes again essentially inactive breasts with an occasional focal calcification within the ducts. After two weeks of perchlorate blockade, there is some duct proliferation and dilation, lobular hyperplasia, and some associated secretory activity. A striking focal calcific phenomenon is noted;

calcospherites or psammoma bodies, numerous and of fair size, are found at both duct and lobular levels and fibrous expansion about parenchymal elements is seen (Fig 2). After 16 hours of access to normal drinking water, there is a mild regression and waning of the lobular hyperplasia and fibrous stromal patches.

Fifty-two-Week-Old Rat Breasts (Group 3).—The control breasts in these older rats show some further histologic alterations, mainly a moderate focal fibrosis, some entrapment of ducts and lobules but no true cytologic atypia. However, the perchlorate blockade in this oldest age group has produced an interesting array of changes in the breast structure and involving more extensive regions. There is a prominent fibrous reaction at the lobular level that bears a great resemblance to the early sclerosing adenosis of the human female (Fig 3). There is likewise an abso-



Fig 5.—Rat breast, 52 weeks old (group 3, perchlorate blockade). Another site of epithelial atypia associated with prominent cystic alteration. Almost entire lining of pyramidal cyst in center is involved (hematoxylin-eosin, $\times 252$).

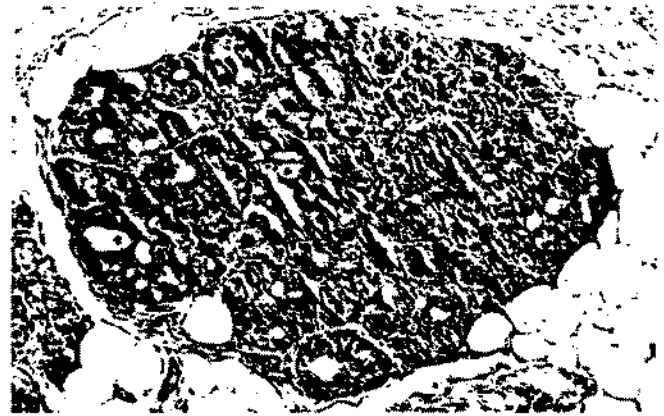


Fig 6.—Rat breast, 52 weeks old (group 3, perchlorate blockade). Focus of tightly packed large cells shows neoplastic or dysplastic transformation. Only quadrant at 12-o'clock to 1-o'clock position hints at previous normal lobular pattern (hematoxylin-eosin, $\times 252$).

Age-related Microscopic Changes in Iodine-Blocked Rat Breasts

Age of Rat, wk	Structural Level	Control	Iodine Deficient, 2 wk	Iodine Deficient, 2 wk; Iodine, 16 hr
16	Ducts	...	Proliferation, 2+ Dilation, 1+ Fibrosis, 1+	Proliferation, 1+ Dilation, 1+
	Lobules	...	Hyperplasia, 3+	Hyperplasia, 2+
	Secretion	...	Secretion, 2+	Secretion, 2+
42	Ducts	Dilation, 1+	Proliferation, 2+ Dilation, 2+ Calcification, 3+	Proliferation, 2+ Dilation, 2+ Calcification, 2+
	Lobules	Hyperplasia, 1+	Hyperplasia, 2+ Fibrosis, 2+	Hyperplasia, 1+ Fibrosis, 1+
	Secretion	...	Secretion, 2+	Secretion, 2+
52	Ducts	Fibrosis, 1+ Calcification, 1+	Proliferation, 1+ Dilation, 2+ Fibrosis, 1+ Papillomatosis, 1+ Atypia, 1+	Proliferation, 1+ Dilation, 2+ Calcification, 1+ Atypia, 1+
	Lobules	Fibrosis, 1+ Adenoma, 1+	Hyperplasia, 1+ Fibrosis, 3+ Atypia, 1+	Fibrosis, 2+ Atypia, 1+ Neoplastic focus, 1+ Adenosis, 1+ Adenoma, 1+
	Secretion	Secretion, 1+	Secretion, 2+	Secretion, 3+

...ute increase in the epithelial ductoacinar concentration. In other areas, there are foci of epithelial atypia and papillomatosis in the lobular clusters (Fig 4). Microcyst formation is apparent in many foci and an increase in fibrous connective tissue invests this altered parenchyma.

On access to 16 hours of untreated drinking water, there is surprisingly little regression of the variegated architecture observed when the breast was iodine blocked. There are foci of duct proliferation, large gritty-appearing "impacted" calcospherites, noticeably distended ducts, and acini filled with secretion. Within these areas of distension, small sites of piled up, disorderly, or pleomorphic epithelial atypia are noted (Fig 5). Other findings in this oldest age group are foci of lobular hyperplasia resembling adenosis; within some of these, there is atypism of the entire lobule. One focus of concern showed a closely packed cellularity, total loss of the "open" acinar pattern, faint basophilia of cytoplasm, nuclear crowding, and early cribriforming (Fig 6).

COMMENT

There seems to be considerable change in the breast parenchyma of the female rat with advancing age. In a tabular fashion, one can record these changes as 1+ to 3+, with the

greatest number representing the greater degree of change (Table). However, with perchlorate blockade of the breast and thus restriction of available iodine, the histopathologic changes are even more pronounced at each of the three different ages. Furthermore, the spectrum of structural deviation widens in the oldest breasts. And these changes encompass both the stromal as well as the epithelial elements.

Evaluation of the fibrosis with respect to its topographical distribution was a bit more puzzling. Although it is focally periductal in the younger rat breasts, and focally intralobular and interlobular in the older ones, there is a stromal fibrous reaction that occurs out in the abundant adipose areas in the older rats to a variable degree. We believe that further investigation of the fibrosing phenomenon in iodine-deficient breasts is warranted for its relation to aging is still unclear. Likewise, the proclivity to duct proliferation under the iodine blockade occurs at all ages.

To our knowledge, relatively little work has been done with older rats and such investigations are in their incipiency. Iodine is essential to the function of the thyroid gland and our preliminary evidence suggests a similar mechanism in the breast. With aging, both the breast and thyroid transport less iodine and there is considerable evidence relating iodine

deficiency to breast cancer development in humans and rodents.¹⁻⁴ It has also been recently suggested in pursuing the relationship between experimental iodine deficiency and breast hyperplasia, atypia, and possible neoplasia, that a common protein carrier may exist. We have discovered in recent experiments a small protein (10,000 to 20,000 daltons) in active breast tissue and a similar protein in the active thyroid gland.⁵ Thus, there is a possibility that iodine mediates its role via protein iodination, and changes brought about by aging may affect this pathway because preliminary studies with older rats have shown end-iodine uptake changes.⁶

The interpretation of the histopathologic patterns is of considerable interest (Table). The rat breast with free access to dietary iodine shows a mild alteration of structure with aging manifested by focal fibrosis, occasional calcifications, and adenomata. With iodine deficiency for two weeks, there is an increased change of focal fibrosis and duct proliferation

not well correlated with age. However, with this deficiency circumstance, there are age-related changes in the form of prominent calcifications, decreased lobular hyperplasia, focal papillomatosis, microcysts, and focal atypia. On access to iodine in the final 16 hours of the two-week period, certain further changes are noted in the oldest rats, these being noticeable secretory activity, focal adenosis, and a highly suspicious neoplastic or dysplastic focus. Thus, iodine deficiency and aging seems to act cumulative-

ly to produce changes closely resembling the spectrum of fibrocystic disease and disturbing epithelial patterns. The findings of distinct and worrisome dysplastic and atypical changes in rat-breast epithelium related to aging in these deficient animals is of sufficient interest so as to suggest the greater use of the older animals by other investigators. In this manner, the obvious discrepancy of age between young animal models and older humans is substantially reduced.

References

1. Eskin BA, Bartuska DG, Dunn MR, et al: Mammary gland dysplasia in iodine deficiency. *JAMA* 200:691-693, 1967.
2. Aquino TI, Eskin BA: Rat breast structure in altered iodine metabolism. *Arch Pathol* 94:280-285, 1972.
3. Eskin BA, Shuman R, Krouse T, et al: Rat breast gland atypia produced by iodine blockade with perchlorate. *Cancer Res* 35:2332-2339, 1975.
4. Eskin BA: Iodine metabolism and breast cancer. *Trans NY Acad Sci* 32:911-952, 1970.
5. Shivetskii AV: Distribution of breast cancer in a goiter district of Northern Bukovina. *Vrach*

Delo 7:37-41, 1968.

6. Koszarowski T, Gadomska H, Warda B, et al: Prevalence of malignant neoplasms of the breast in Poland in selected areas (1962-1965). *Pol Tyg Lek* 23:933-935, 1968.
7. Eskin BA, Sparks CE, LaMont B, et al: Protein iodination in the breast and thyroid of rats. *Proc Endocrine Soc*, to be published.
8. Eskin BA: Iodine and mammary cancer. in Schrauzer G (ed): *Inorganic and Nutritional Aspects of Cancer*. New York, Plenum Press, 1977, pp 293-304.